

Frontal Sinus Recognition Using Image Foresting Transform and Shape Context

¹Juan Rogelio Falguera, ²Fernanda Pereira Sartori Falguera and ³Aparecido Nilceu Marana
UNESP – School of Sciences – Department of Computing – Bauru – SP – Brazil
{¹juan.falguera, ²fernanda.sartori}@mstech.com.br
³nilceu@fc.unesp.br

Abstract

It has been established in prior investigations that the radiographic pattern of frontal sinus is highly variable and unique for every individual. This paper presents a frontal sinus recognition method, for human identification, based on DIFT and Shape Context algorithms. Experimental results show the effectiveness of the proposed method.

1. Introduction

The frontal sinus is located in the frontal bone, and consists of paired, irregularly shaped, loculated cavities, which communicate with the nasal fossa via the infundibulum (Figure 1). It starts developing embryonically from an ethmoidal cell during the second year of life, reaching its maximum size at the age of twenty, and remaining stable through the rest of the life. The configuration of the frontal sinus is claimed to be unique for each individual, even for monozygotic twins [1,2,3].

Some authors have suggested the possibility of identifying a person by comparing frontal sinus radiographs. Most of the previous studies, frontal sinus patterns were manually recognized [2,3]. Marana et al [4] investigated frontal sinus descriptors in order to find the best features to be used in automatic or semi-automatic frontal sinus identification systems. They obtained 11.56% of equal error rate when the features: area, width, and Feret's diameter were used as frontal sinus descriptors.

The goal of this work is to investigate, besides the most proper features, the best segmentation algorithms in order to improve the frontal sinus recognition rates while minimizing the human intervention during the process.

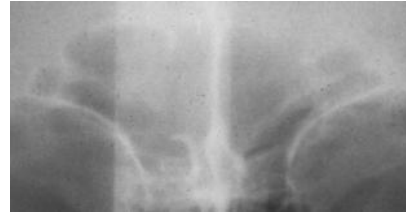


Figure 1. Frontal sinus image obtained from a radiograph.

2. Frontal Sinus Segmentation

The frontal sinus segmentation from a x-ray of the whole braincase has been shown the most difficult step for automatic frontal sinus recognition, since the precise edges of the frontal sinus are very difficult to find due to interferences of other braincase structures and some other noises. Even for radiologists this can be a difficult task. Figure 2 shows the manual segmentation obtained, under the supervision of a radiologist, for the frontal sinus image presented in Figure 1.

In this work we adopted the DIFT (Differential Image Forest Transform) algorithm [5] for frontal sinus segmentation. This algorithm reduces the user interaction to some chosen points (seeds) inside and outside the interest area. Figure 3 presents the segmentation of the frontal sinus of the Figure 1, by using the DIFT algorithm. It is possible to observe that DIFT segmentation is very similar to the manual segmentation.

The manual segmentation was adopted as the ground truth during the evaluation of the effectiveness of the DIFT algorithm.

3. Frontal Sinus Matching

The Shape Context method [6] was adopted in this work in order to align and compare the frontal sinus

shapes extracted from the segmented images. This method attaches a descriptor, the shape context, to each point on the shape. The shape context at a reference point captures the distribution of the remaining points relative to it, offering a global discriminative characterization. Corresponding points on two similar shapes have similar shape contexts [6].

The similarity between two frontal sinuses is computed as the minimum sum of matching errors between corresponding points found in their shapes.

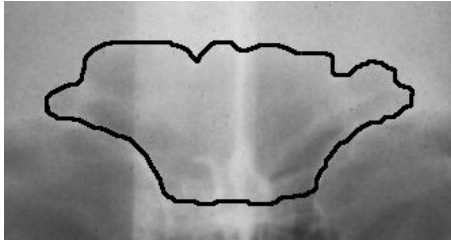


Figure 2. Manual segmentation of the frontal sinus presented in Figure 1, carried out under a human expert supervision.

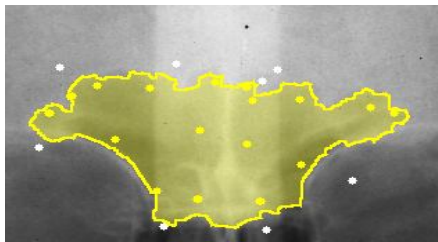


Figure 3: Semi-automatic frontal sinus segmentation using the DIFT algorithm.

4. Experimental Results

The performance of the proposed method for frontal sinus recognition was evaluated on a database consisting of 90 antero-posterior (AP) radiographs of 29 individuals older than 20-years-old. There were at last two radiograph images per individual.

Figure 4 shows a receiver operating characteristic (ROC) curve, which plots the false acceptance rate (FAR) versus the genuine acceptance rate (GAR) for different threshold values. The proposed method obtained 5,82% of equal error rate (EER) for the used database, a very good result.

5. Conclusion

The proposed method for frontal sinus recognition using DIFT and Shape Context obtained very good results in our experiments, better than the previous

results reported by Marana et al. [4]. These results, due to the effectiveness of the DIFT algorithm used in the segmentation stage, have stimulated new investigations that will include the use of the other frontal sinus descriptors together with shape in order to reduce even more the error rates.

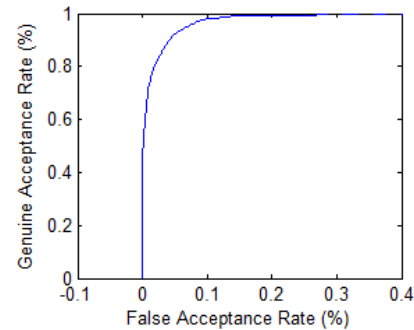


Figure 4. Receiver Operating Characteristic curve for the proposed frontal sinus recognition method.

Acknowledgements

The authors thank Dr S. L. Brooks, Dr J. McNamara, University of Michigan, USA, for providing access to the frontal sinus radiograph archives, and Dr. Flavia Casedei, from Hospital Estadual de Bauru, for her help during the manual frontal sinus segmentation. Aparecido Nilceu Marana thanks Fapesp (proc. 2007/04172-0).

References

- [1] Schuller, A.. A note on the identification of skulls by x-ray pictures of the frontal sinuses. *Med. J. Australia*, 1943, 1:554-7.
- [2] Kirk, N. J.; Wood, R. E.; Goldstein, M.. Skeletal Identification Using the Frontal Sinus Region: A Retrospective Study of 39 Cases. *J Forensic Sci* 2002, 47(2):318-323.
- [3] Ribeiro, F. A. Q.. Standardized measurements of radiographic films of the frontal sinuses: An aid to identifying unknown persons. *Ear, Nose and Throat Journal*, Jan 2000, v79, p26.
- [4] Marana, A. N., Oura, D. Y., Yamamoto, T., Falguera, F. P. S., and Falguera, J. R.; Towards an Automatic Frontal Sinus Identification System, *Anais do II Workshop de Visão Computacional, USP - São Carlos*, 2006. p. 93-98.
- [5] Falcão, A. X. and Bergo, F. P. G.. Interactive volume segmentation with differential image foresting transforms. *IEEE Trans. on Medical Imaging*, 23(9):1100-1108, 2004.
- [6] Belongie, Serge; Malik, Jitendra; Puzicha, Jan. Shape Matching and Object Recognition using Shape Contexts. *IEEE Transactions on Pattern Analysis and Machine Intelligence*, April 2002, vol. 24, No. 24, p. 509-522.